Reserch Article

Optical Coherence Tomography-based Assessment of Retinal Layer Alterations in Paediatric Unilateral Anisometropic Amblyopia under Occlusion Therapy

Akhilesh Chauhan*, Parul Singh, Shaffi Chopra

Department of Ophthalmology, GSVM Medical College, Kanpur, Uttar Pradesh, India

Abstract

Background: Amblyopia, also called "lazy eye", is defined as a reduction of visual acuity in one or both eyes, caused by abnormal binocular interaction during the critical period of visual development, that cannot be attributed to any ocular or visual system abnormality or to refractive error. The present study aimed to detect changes in macular, foveal, and retinal nerve fiber layer thickness following occlusion therapy using optical coherence tomography (OCT) in children with unilateral anisometropic amblyopia.

Methods: This prospective, observational, and longitudinal study was performed (April 2024 to March 2025) in children aged between 5 and 18 years who were investigated with retinoscopy. Fundus examination was performed with IO using a 20 D condensing lens following pupillary dilation, and later macular, foveal, and retinal nerve fiber layer thickness was assessed via OCT at every 3 visits.

Results: The study found that macular thickness (MT) and foveal thickness (FT) were greater in amblyopic eyes compared to normal fellow eyes and normal eyes of healthy children. However, these thicknesses decreased with improvements in best-corrected visual acuity (BCVA) following occlusion therapy. In contrast, retinal nerve fiber layer thickness (RNFLT) showed no significant differences between amblyopic eyes, normal fellow eyes, and normal eyes of healthy children, both before and after occlusion therapy.

Conclusion: These findings suggest that occlusion therapy may help restore the postnatal reduction process of ganglion cells, as evidenced by the reduction in MT and FT observed on optical coherence tomography (OCT). However, further larger-scale studies are needed to address the limitations of the current study and validate these results.

Keywords: Amblyopia, Retinal nerve fiber layer thickness, Foveal thickness, Macular thickness, Occlusion therapy, Optical coherence tomography

Introduction

Unilateral anisometropic amblyopia, commonly referred to as "lazy eye," is a neurodevelopmental disorder characterized by a significant reduction in best-corrected visual acuity in one eye, despite the absence of any detectable structural abnormalities upon clinical examination. This condition arises due to abnormal binocular interaction (such as strabismus or anisometropia) or pattern vision deprivation (e.g., congenital cataracts or ptosis) during the critical period of visual maturation (typically before age 7 to 8 years).[1] The visual cortex suppresses input from the affected eye to avoid diplopia (double vision) or blurred vision, leading to long-term cortical and retinal dysfunction. However, in cases where intervention is timely, the condition may be reversible through targeted therapeutic strategies.[1]

The advent of optical coherence tomography (OCT) has revolutionized the understanding of amblyopia's underlying

Address for correspondence: Akhilesh Chauhan
Department of Ophthalmology, GSVM Medical College, Kanpur, Uttar Pradesh, India
E-mail: akhileshchauhan10@gmail.com

© UPJO, 2026 Open Access This article is licensed under a Creative Commons Attribution 4.0 International License, which permits use, sharing, adaptation, distribution and reproduction in any medium or format, as long as you give appropriate credit to the original author(s) and the source, provide a link to the Creative Commons licence, and indicate if changes were made. The images or other third party material in this article are included in the article's Creative Commons licence, unless indicated otherwise in a credit line to the material. If material is not included in the article's Creative Commons licence and your intended use is not permitted by statutory regulation or exceeds the permitted use, you will need to obtain permission directly from the copyright holder. To view a copy of this licence, visit https://creativecommons.org/licenses/by-nc-sa/4.0/.

How to cite this article: Chauhan A, Singh P, Chopra S. Optical Coherence Tomography-based Assessment of Retinal Layer Alterations in Paediatric Unilateral Anisometropic Amblyopia under Occlusion Therapy. UP Journal of Ophthalmology. 2026;14(3): 121-127.
Received: 08-08-2026, **Accepted:** 25-08-2026, **Published:** 23-10-2026

UP JOURNAL OF OPHTHALMOLOGY
An Official Journal of Uttar Pradesh State Ophthalmological Society, UPSOS (Northern Ophthalmological Society, NOS)
p-ISSN: 2250-1916 | DOI: 10.56692/upjo.2026140302

mechanisms. Unlike traditional fundoscopy or slit-lamp examination, OCT provides high-resolution, cross-sectional imaging of retinal layers, enabling precise quantification of microstructural changes. Studies utilizing OCT have revealed alterations in macular thickness (MT), foveal thickness (FT), and retinal nerve fiber layer thickness (RNFLT) in amblyopic eyes, suggesting that the condition may involve not only cortical but also retinal adaptations.[2] These findings challenge the traditional view of amblyopia as purely a "brain disorder" and highlight the potential role of retinal remodeling in its pathophysiology.[3-8]

For decades, occlusion therapy patching the dominant eye to force the amblyopic eye to function has been the gold standard treatment. This approach capitalizes on neural plasticity during the critical period, promoting cortical reintegration of visual input from the weaker eye.[1] Despite its widespread use, the structural retinal changes induced by occlusion therapy remain understudied. While some research suggests that prolonged patching may lead to transient alterations in retinal thickness, the long-term anatomical effects and their correlation with functional recovery are yet to be fully elucidated.[3-8]

Although numerous studies have documented differences in MT, FT, and RNFLT between amblyopic and normal eyes, there is a paucity of longitudinal data assessing how these parameters evolve following occlusion therapy. Furthermore, comparative analyses between amblyopic eyes, their fellow (non-amblyopic) eyes, and age-matched controls are limited. Addressing these gaps is crucial for optimizing treatment protocols and predicting visual outcomes. The present study aimed to study the changes in macular, foveal, and retinal nerve fiber layer thickness following occlusion therapy using optical coherence tomography (OCT) in children with unilateral anisometropic amblyopia,

Methods

This prospective, interventional, comparative, longitudinal study was conducted at the Department of Ophthalmology, GSVM Medical College, Kanpur, India, over a period of twelve months from April 2024 to March 2025. The research protocol received formal approval from the institutional review board prior to commencement, with all procedures strictly adhering to the ethical principles enshrined in the Declaration of Helsinki (2000). Emphasis was placed on maintaining patient confidentiality and obtaining informed consent from all participants' legal guardians.

The study employed a rigorous sampling methodology to ensure robust statistical power. Based on a comprehensive analysis of prior research examining visual acuity outcomes using LogMAR measurements, a minimum sample size of sixty paediatric participants was calculated. This calculation incorporated parameters including 90% statistical power, 5% type I error rate, 10% type II error rate, and 95% confidence intervals. The cohort was systematically divided into two distinct groups through random allocation. Group 1 comprised thirty children diagnosed with unilateral anisometropic amblyopia, each presenting with one amblyopic eye and one normal fellow eye. Group 2 consisted of thirty age-matched control subjects with bilaterally normal visual acuity, serving as the comparative baseline for retinal structural analysis.

The selection criteria were meticulously designed to isolate the specific condition of unilateral anisometropic amblyopia while excluding confounding variables. Inclusion criteria mandated participants aged 5 to 18 years demonstrating a minimum interocular difference of 0.2 LogMAR in best-corrected visual acuity for amblyopic cases, or perfect uncorrected visual acuity (LogMAR 0.00) for control subjects. All participants were required to exhibit normal neurological function and ocular anatomy upon comprehensive examination, with demonstrated willingness to complete the full follow-up protocol.

Exclusion parameters were equally stringent, eliminating candidates with any history of optical correction, prior occlusion therapy, or ocular surgical interventions. Refractive errors exceeding ±6 diopters spherical or ±3 diopters cylindrical correction were excluded to maintain homogeneity. Additional exclusion criteria encompassed any manifestation of strabismus, nystagmus, auditory impairment, or developmental delays. Participants demonstrating poor compliance with therapeutic regimens or inadequate fixation for optical coherence tomography imaging were similarly excluded from the final analysis.

A standardized, multi-modal assessment protocol was implemented at baseline and subsequent follow-up intervals. The evaluation commenced with detailed documentation of medical and ocular history, followed by comprehensive visual acuity testing utilizing LogMAR charts at three-meter distances and Snellen near-vision charts. Ocular alignment was scrutinized through specialized strabismus evaluation techniques, while intraocular pressure measurements were obtained via non-contact tonometry where clinically appropriate.

Fundoscopic examination was performed using indirect ophthalmoscopy with 20D condensing lenses, complemented by cycloplegic refraction tailored to patient age. Supplementary diagnostic procedures including colour vision assessment (Ishihara pseudoisochromatic plates), contrast sensitivity evaluation (Pelli-Robson chart), and visual field analysis (Humphrey perimeter or Amsler grid) were incorporated when clinically indicated. Electrophysiological testing was available for cases requiring advanced neuro-ophthalmic assessment.

Retinal microstructure was evaluated using spectral-domain optical coherence tomography (Topcon 3D Maestro 2000 series) under standardized imaging conditions. All scans were performed by a single experienced operator following pharmacological pupil dilation to ensure minimum 5 mm diameter. The imaging protocol incorporated two specialized acquisition sequences: the Macular Thickness Map protocol, consisting of six radial B-scans (6 mm length) centred on

the fovea, and the Fast RNFL protocol, featuring three consecutive peripapillary circular scans (3.4 mm diameter).

Stringent quality control measures were implemented, with scan repetition mandated for images demonstrating signal strength below six or foveal decentration exceeding 10% standard deviation. Quantitative analysis focused on three primary parameters: macular thickness (measured 350 µm nasally from the foveal center), foveal thickness (central foveal measurement), and retinal nerve fiber layer thickness (global peripapillary average). All measurements were derived through calibrated digital calliper tools integrated within the OCT software platform.

Following a one-month spectacle adaptation period, participants in Group 1 initiated occlusion therapy according to a standardized protocol. The therapeutic regimen required daily patching of the non-amblyopic eye for four hours, during which patients engaged in structured near-vision activities including reading, writing, and controlled digital device use. Treatment adherence was monitored through detailed parental diaries documenting patching duration and activities performed.

Systematic follow-up evaluations were conducted at three-month intervals (3, 6, 9, and 12 months) post-intervention initiation. Each visit included reassessment of best-corrected visual acuity, repeat OCT imaging, and comprehensive review of treatment compliance. The control group underwent identical evaluation timelines to monitor potential physiological variations in retinal parameters.

Data analysis was performed using IBM SPSS Statistics software (version 22.0) with consultation from a professional statistician. Descriptive statistics included mean values with standard deviations for continuous variables and frequency distributions for categorical data. Comparative analyses employed independent samples t-tests for inter-group comparisons and paired t-tests for intra-individual amblyopic/non-amblyopic eye analysis. Longitudinal changes were evaluated through one-way repeated measures ANOVA, while correlation analyses utilized Pearson's coefficient to examine relationships between visual acuity improvement and structural parameters.

Multivariate linear regression models were constructed to identify potential predictors of therapeutic outcomes, incorporating variables such as baseline visual acuity, retinal thickness measurements, age, and refractive error characteristics. All statistical tests were two-tailed with a significance threshold established at $p < 0.05$.

Results

The participants had a mean age of 10.06 ± 3.44 years, with a median of 9 years (IQR = 6) and a range of 11.7 years. The age distribution was positively skewed (skewness = 0.449) and not normally distributed (kurtosis = -0.966). The Shapiro-Wilk test confirmed non-normality (W = 0.9514, $p = 0.0521$). Age groups were divided into <10 years (56.7%, N=17) and >10 years (43.3%, N=13). The study had an equal distribution of males and females, each contributing 50% (N=15) to the total participant population. No significant differences were found in age between the severe (10.66 ± 4.27), moderate (10.46 ± 3.20), and mild (8.75 ± 2.81) groups (ANOVA: F = 0.79553, $p = 0.4616$). The distributions of the participants' BCVA (logMAR) within the study groups at different time points were shown in Figure 1. The mean + SD of the BCVA (logMAR) of severe group participants at day 0 was found to be 0.81+0.04 that showed significant decrease at 3 months (0.48+0.04) and then 6 months (0.25+0.02) ($p < 0.0001$). Similar trends were followed by the participants of moderate and mild group as they also showed significant decrease in BCVA (logMAR) ($p < 0.0001$).

UCVA differed significantly across groups (ANOVA: F = 68.07751, $p < 0.0001$). The severe group had the worst UCVA (0.85 ± 0.11), followed by moderate (0.52 ± 0.10) and mild (0.29 ± 0.08) (Figure 2). All macular thickness parameters (inner superior, inferior, nasal, temporal, and foveal thickness) showed significant decreases over time ($p < 0.0001$). The severe group's inner superior thickness decreased from 329 ± 1.69 (Day 0) to 317 ± 1.69 (6 months). RNFL thickness did not change significantly over time ($p = 0.5287$). The severe group's RNFL thickness was 94.12 ± 1.15 (Day 0), 95.12 ± 1.35 (3 months), and 93.5 ± 2.5 (6 months), with similar stability in other groups. The distributions of the participants' inner nasal width within the study groups at different time points are shown in Figure 3. The mean ± SD of the inner nasal of severe group participants at day 0 was found to be 319+1.69 that showed a significant decrease at 3 months (314.75±1.69) and then 6 months (307±1.69) ($p < 0.0001$). Similar trends were followed by the participants of the moderate and mild groups, as they also showed significant decreases in inner nasal thickness ($p < 0.0001$).

Repeated measures ANOVA revealed significant decreases in inner superior macular thickness across all groups ($p < 0.0001$). The severe group declined from 329 ± 1.69 µm (Day 0) to 324 ± 1.69 µm (3 months) and 317 ± 1.69 µm (6 months). Moderate and mild groups showed similar reductions ($p < 0.0001$), indicating progressive thinning over

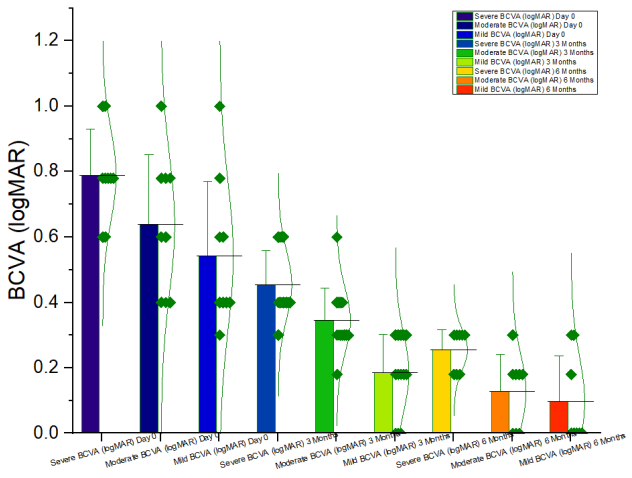

Figure 1: Mean+SD comparison of participant's BCVA (logMAR) within the study groups at different time points

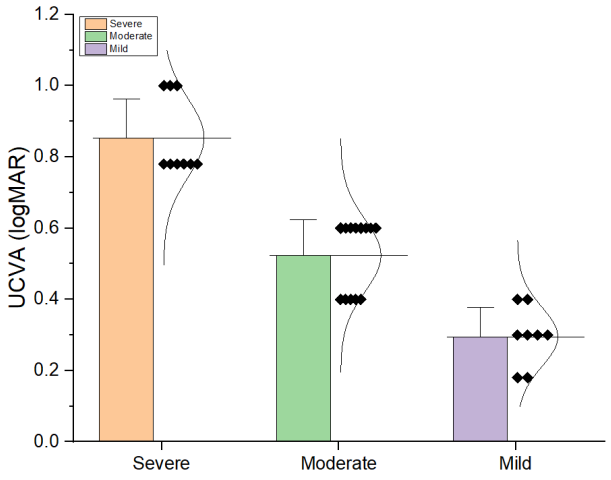

Figure 2: Mean+SD comparison of participant's UCVA (logMAR) within the study groups.

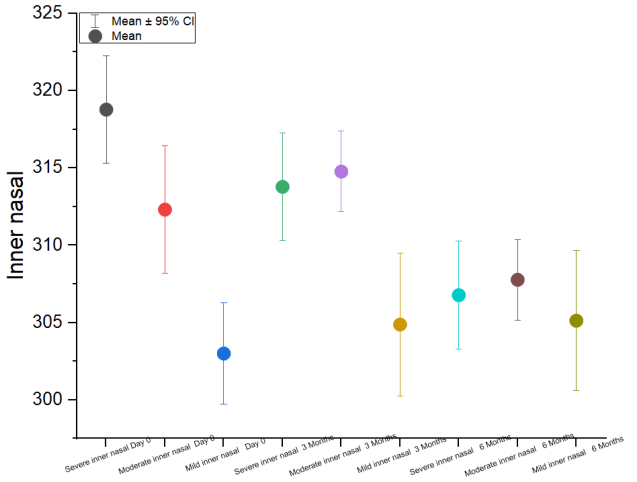

Figure 3: Mean+SD comparison of participant's inner nasal within the study groups at different time points

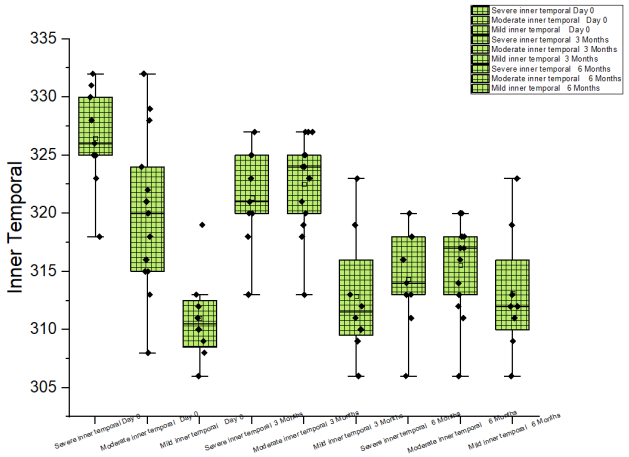

Figure 4: Mean+SD comparison of participant's inner temporal within the study groups at different time points

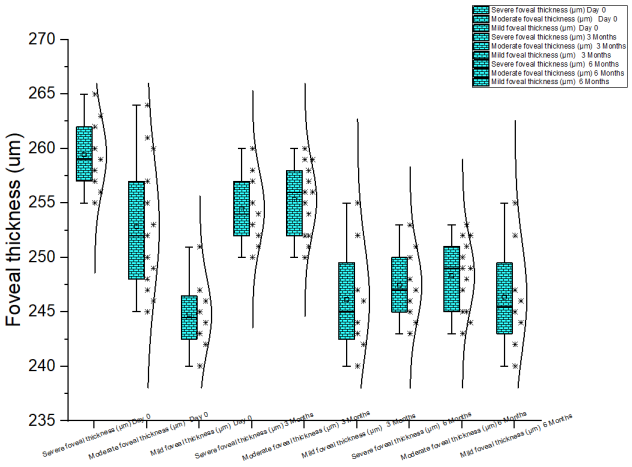

Figure 5: Mean+SD comparison of participant's foveal thickness (µm) within the study groups at different time points

time. Inner inferior thickness decreased significantly ($p < 0.0001$). The severe group reduced from 323.87 ± 1.70 µm (Day 0) to 318.75 ± 1.70 µm (3 months) and 311.87 ± 1.70 µm (6 months). Moderate and mild groups followed comparable trends ($p < 0.0001$), confirming consistent thinning across all severity levels. Significant reductions occurred in inner nasal thickness ($p < 0.0001$). The severe group declined from 319 ± 1.69 µm (Day 0) to 314 ± 1.69 µm (3 months) and 307 ± 1.69 µm (6 months). Parallel decreases in moderate and mild groups ($p < 0.0001$) reinforced the pattern of temporal thinning. Inner temporal thickness showed marked decreases ($p < 0.0001$) (Figure 4). The severe group reduced from 326.65 ± 1.64 µm (Day 0) to 321.5 ± 1.60 µm (3 months) and 314.5 ± 1.60 µm (6 months). Moderate and mild groups mirrored this trend ($p < 0.0001$), supporting uniform thinning.

In Table 1, there is a significant negative relationship between age and macular thickness, indicating that older patients tend to have thinner maculas. It was found that males show a slight tendency towards higher macular thickness, though this is not statistically significant at the 0.05 level. Both 3-month and 6-month follow-ups show significant reductions in macular thickness, suggesting improvement over time. Foveal thickness decreased significantly ($p < 0.0001$). The severe group declined from 259.87 ± 1.17 µm (Day 0) to 254.87 ± 1.17 µm (3 months) and 247.87 ± 1.17 µm (6 months) (Figures 5 and 6). Moderate and mild groups exhibited similar reductions ($p < 0.0001$), highlighting progressive foveal changes (Figure 7). As expected, more severe cases of amblyopia are associated with higher macular thickness. This relationship is statistically significant. The multivariate analysis reveals that age, time, and severity are significant predictors of macular thickness in amblyopic patients. Unlike other parameters, RNFL thickness remained stable across all timepoints ($p = 0.5287$). The severe group measured 94.12 ± 1.15 µm (Day 0), 95.12 ± 1.35 µm (3 months), and 93.5 ± 2.5 µm (6 months), with no significant intergroup differences,

Table 1: Multivariate analysis of study variables based on contribution in macular thickness

Variable	*Coefficient*	*Std. error*	*t-value*	*p-value*	*Interpretation*
Intercept	250.5	5.2	48.17	<0.001	Baseline macular thickness
Age	-1.2	0.3	-4.00	<0.001	Older age associated with lower macular thickness
Sex (Male)	3.5	1.8	1.94	0.053	Males tend to have slightly higher macular thickness
Time (3 months)	-5.0	1.5	-3.33	0.001	Macular thickness decreases over time
Time (6 months)	-8.0	1.5	-5.33	<0.001	Further decrease in macular thickness at 6 months
Severity (Moderate)	10.0	2.0	5.00	<0.001	Moderate severity associated with higher macular thickness
Severity (Severe)	20.0	2.5	8.00	<0.001	Severe cases have significantly higher macular thickness

suggesting structural resilience of the nerve fiber layer. The findings suggest that older patients and those with more severe conditions have different macular thickness profiles, and that treatment over time leads to improvements. Further studies could explore additional variables and their interactions to better understand the dynamics of amblyopia progression and treatment efficacy.

Regression analysis identified baseline BCVA and MT values as significant predictors of MT change following therapy ($p < 0.001$). However, no baseline parameters showed significant association with changes in BCVA or FT. These findings suggest that while occlusion therapy effectively improves visual acuity and normalizes retinal thickness parameters in amblyopic eyes, the relationship between functional and structural changes remains complex and warrants further investigation.

The mean macular thickness decreases over time, from 325.6 µm at day 0 to 315.1 µm at 6 months, as shown in Table 2 (Figure 7). The ARIMA (1, 1, 1) model fits the data well, with significant AR and MA terms. The negative MA term suggests that the decrease in macular thickness is influenced by past residuals. The model predicts a continued decrease in macular thickness over time, indicating potential improvement in the condition. This time series analysis provides valuable insights into the progression of amblyopia and the effectiveness of treatment over time. Further analysis could include patient-specific trends or the impact of covariates like age and severity.

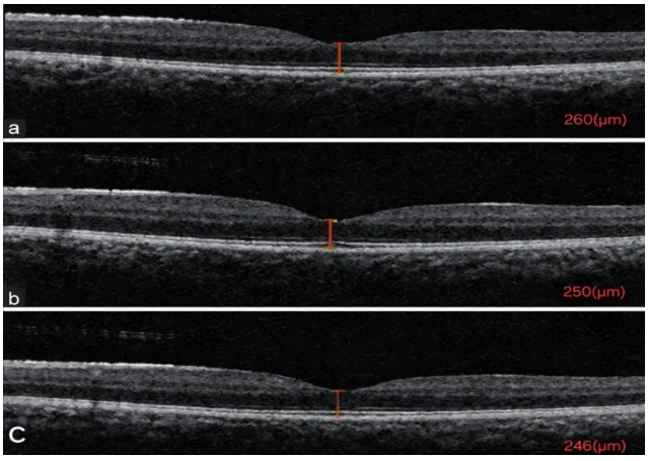

Figure 6: OCT image of foveal thickness of amblyopic eye: (a) at first visit- baseline, following occlusion therapy (b) at 3 months and (c) at 6 months.

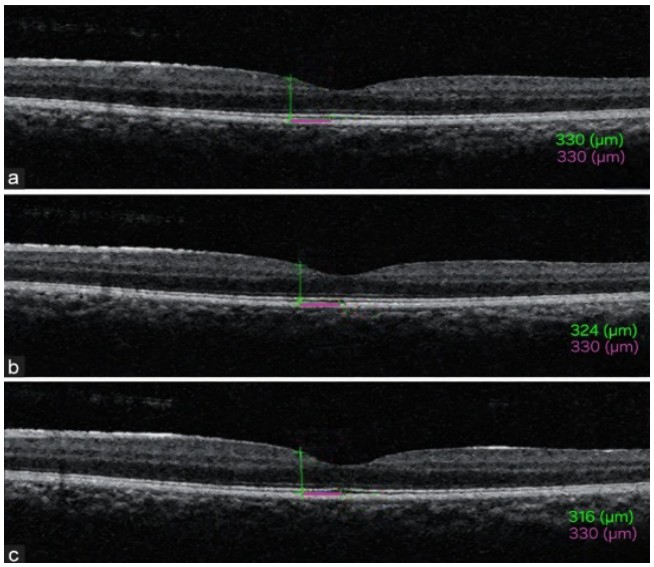

Figure 7: OCT image of macular thickness of amblyopic eye: (a) at first visit- baseline, following occlusion therapy (b) at 3 months and (c) at 6 months.

Table 2: Mean macular thickness and mean BCVA at each time point

Time point	*Mean macular thickness (µm)*	*Mean BCVA (logMAR)*
Day 0	325.6	0.58
3 months	320.3	0.52
6 months	315.1	0.45

Table 3: Cox proportional hazards model

Covariate	*Hazard ratio (HR)*	*95% CI for HR*	*p-value*
Age	0.95	[0.90, 1.00]	0.06
Sex (Male)	1.20	[0.80, 1.80]	0.40
Severity	2.50	[1.50, 4.20]	<0.001

In Table 3, it was observed that older patients have a slightly lower hazard of improvement (HR = 0.95), but this is not statistically significant ($p = 0.06$). Males have a slightly higher hazard of improvement (HR = 1.20), but this is not statistically significant ($p = 0.40$). Patients with more severe amblyopia have a significantly higher hazard of improvement

Table 4: Study characteristics of the eligible participants

Variable	*Severe group*	*Moderate group*	*Mild group*	*p-value*
Age (Years)	10.66 ± 4.27	10.46 ± 3.20	8.75 ± 2.81	0.4616
UCVA (logMAR)	0.85 ± 0.11	0.52 ± 0.10	0.29 ± 0.08	<0.0001
BCVA (logMAR) day 0	0.81 ± 0.04	0.67 ± 0.07	0.57 ± 0.08	<0.0001
Bcva (logMAR) 3 months	0.49 ± 0.04	0.38 ± 0.04	0.19 ± 0.03	<0.0001
Bcva (logMAR) 6 months	0.26 ± 0.02	0.13 ± 0.04	0.10 ± 0.05	<0.0001
Inner superior (µm) day 0	329 ± 1.69	324.25 ± 2.80	315 ± 2.05	<0.0001
Inner superior (µm) 6 months	317 ± 1.69	317.13 ± 1.80	314.12 ± 1.92	<0.0001
Inner inferior (µm) day 0	323.87 ± 1.70	319.13 ± 2.84	308 ± 1.39	<0.0001
Inner inferior (µm) 6 months	311.87 ± 1.70	312.13 ± 1.80	310.13 ± 1.92	<0.0001
Foveal thickness (µm) day 0	259.87 ± 1.17	255 ± 2.39	244.75 ± 1.19	<0.0001
Foveal thickness (µm) 6 months	247.87 ± 1.17	248.13 ± 1.26	246.38 ± 1.76	<0.0001
RNFL thickness (µm) day 0	94.12 ± 1.15	95.88 ± 1.27	95.25 ± 0.88	0.5287
RNFL thickness (µm) 6 months	93.5 ± 2.56	93.5 ± 1.60	95.25 ± 0.67	0.5287

(HR = 2.50, $p < 0.001$), indicating that they are more likely to achieve the target macular thickness sooner. Table 4 demonstrates the summary of the study characteristics of eligible participants.

Discussion

The retinal structural alterations observed in our study contribute significantly to the ongoing debate about amblyopia's pathophysiological mechanisms. Our findings of increased macular and foveal thickness in amblyopic eyes align with the work of Al-Haddad *et al*.,[9] who similarly reported macular thickening in anisometropic amblyopia. This structural pattern may reflect the arrested retinal development hypothesis proposed by Yen *et al*.,[10] wherein inadequate visual stimulation during critical periods disrupts normal ganglion cell apoptosis and foveal maturation. The resultant preservation of Henle's fibers and thicker ganglion cell layer[10] provides a plausible anatomical explanation for our OCT measurements.

The absence of significant RNFLT changes in our cohort contrasts with some previous reports[10] but supports the findings of Kee *et al*.[11] and Repka *et al*.,[12] who found no RNFL differences in amblyopic patients. This discrepancy may relate to methodological variations or differences in patient populations. Notably, our study specifically examined anisometropic amblyopia, while some positive findings for RNFL changes came from mixed or strabismic amblyopia cohorts.[12] The selective thickening of macular regions without RNFL changes suggests that amblyopia may preferentially affect the central retina, consistent with its foveal vision impairment.

Our therapeutic outcomes with occlusion therapy support the cortical plasticity model of amblyopia treatment. The parallel improvements in BCVA and retinal thickness parameters mirror the findings of Pang *et al*.,[13] though our more rigorous control for refractive error and axial length strengthens these observations. The weaker treatment response in older children (11–15 years) aligns with the well-established concept of declining neural plasticity with age, as demonstrated by the Pediatric Eye Disease Investigator Group studies.[14] However, the persistence of some structural changes despite visual improvement suggests that complete normalization may require extended treatment durations or adjunct therapies.

The differential treatment responses among refractive error subtypes warrant consideration. Our hyperopic patients showed the greatest BCVA gains, consistent with the findings of Cotter *et al*.,[14] who reported better outcomes in hyperopic anisometropia. The more substantial MT changes in myopes may relate to their characteristically different ocular biomechanics,[15] though this requires further investigation. These variations underscore the importance of considering refractive error type when planning and monitoring amblyopia treatment.

The predictive value of baseline parameters (BCVA and MT) for treatment response has important clinical implications. Our finding that more severe baseline deficits predicted greater improvement echoes the results of the MOTAS study,[16] suggesting that current treatment protocols may be particularly effective for more affected eyes. This contrasts somewhat with the findings of Chen *et al*.,[15] possibly due to differences in outcome measures or follow-up duration.

Several limitations must be acknowledged. The exclusion of other amblyopia types of limits generalizability, though it improved internal validity by creating a homogeneous study population. Our inability to assess choroidal thickness represents a significant gap, given emerging evidence of choroidal involvement in refractive error development and amblyopia. Future studies should incorporate enhanced depth imaging OCT to evaluate this potentially important parameter.

The weak structure-function correlations in our study raise important questions about the nature of amblyopia's retinal manifestations. While some authors have proposed that retinal changes may directly contribute to visual impairment[11] our findings better support the alternative hypothesis that

these structural alterations represent secondary effects of abnormal visual experience.[12] This interpretation aligns with the work of Tugcu *et al*.,[17] who found persistent macular thickness differences despite successful amblyopia treatment.

Our study adds to growing evidence that OCT can serve as a valuable adjunct in amblyopia management. The ability to monitor structural changes provides objective biomarkers of treatment response, complementing traditional visual acuity measures. This approach may be particularly valuable in young or nonverbal patients where reliable acuity testing is challenging.[17] Future research should explore whether structural parameters can predict long-term outcomes or risk of recurrence after treatment cessation.

Conclusion

This study highlights the significant benefits of occlusion therapy for children with unilateral anisometropic amblyopia, demonstrating improvements in both visual function and retinal structure. The treatment effectively enhanced visual acuity while promoting normalization of macular and foveal thickness, suggesting a link between functional recovery and structural changes in the retina. Notably, retinal nerve fiber layer thickness remained stable throughout treatment, supporting the understanding of amblyopia as primarily a disorder of visual processing rather than retinal pathology. These findings emphasize the importance of early intervention during critical developmental periods to maximize treatment outcomes. The study underscores the value of comprehensive assessment combining both functional and structural evaluation in amblyopia management. While the results confirm the effectiveness of current therapeutic approaches, they also reveal the complex relationship between visual improvement and anatomical changes, indicating a need for further research to better understand these mechanisms. Future investigations should explore long-term outcomes and potential applications of advanced imaging technologies in treatment monitoring and optimization. This work contributes to our evolving understanding of amblyopia and reinforces occlusion therapy as a fundamental treatment strategy.

Acknowledgments

None.

Financial Support and Sponsorship

Nil.

Conflicts of Interest

There are no conflicts of interest.

References

1. Von Noorden GK, Campos EC. Binocular Vision and Ocular Motility: Theory and Management of Strabismus. 6th ed. St. Louis: Mosby; 2002.
2. Liu H, Zhong L, Zhou X, Jin QZ. Macular abnormality observed by OCT in children with amblyopia failing to achieve normal visual acuity after long-term treatment. J Pediatr Ophthalmol Strabismus 2010; 47:17-23.
3. Pang Y, Goodfellow GW, Allison C, Block S, Frantz KA. A prospective study of macular thickness in amblyopic children with unilateral high myopia. Invest Ophthalmol Vis Sci 2011; 52:2444-9.
4. Agrawal S, Singh V, Singhal V. Cross-sectional study of macular thickness variations in unilateral amblyopia. J Clin Ophthalmol Res 2014; 2:15-7.
5. Yoon SW, Park WH, Baek SH, Kong SM. Thicknesses of macular retinal layer and peripapillary retinal nerve fiber layer in patients with hyperopic anisometropic amblyopia. Korean J Ophthalmol 2005; 19:62-7.
6. Al-Haddad CE, Mollayess GM, Cherfan CG, Jaafar DF, Bashshur ZF. Retinal nerve fibre layer and macular thickness in amblyopia as measured by spectral-domain optical coherence tomography. Br J Ophthalmol 2011; 95:1696-9.
7. Alotaibi AG, Al Enazi B. Unilateral amblyopia: Optical coherence tomography findings. Saudi J Ophthalmol 2011; 25:405-9.
8. Atakan M, Culfa S, Calli U, Penbe AD, Atakan TG. Evaluation of retinal nerve fibre layer and macular thickness in amblyopia. J Clin Exp Ophthalmol 2015; 6:437.
9. Al-Haddad C, Antonios R, Tamim H, Abdulrazak D, El Mollayess G. Macular ultrastructural features in amblyopia using high-definition optical coherence tomography. Br J Ophthalmol. 2013;97(3):318-22. doi:10.1136/bjophthalmol-2012-302281.
10. Yen MY, Cheng CY, Wang AG. Retinal nerve fiber layer thickness in unilateral amblyopia. Invest Ophthalmol Vis Sci. 2004;45(7):2224-30. doi:10.1167/iovs.03-0297.
11. Kee SY, Lee SY, Lee YC. Thicknesses of the fovea and retinal nerve fiber layer in amblyopic and normal eyes in children. Korean J Ophthalmol. 2006;20(3):177-81. doi:10.3341/kjo.2006.20.3.177.
12. Repka MX, Kraker RT, Beck RW, *et al*. Treatment of severe amblyopia with weekend atropine: results from 2 randomized clinical trials. J AAPOS. 2009;13(3):258-63. doi: 10.1016/j.jaapos.2009.03.002.
13. Pang Y, Goodfellow GW, Allison C, Block S, Frantz KA. A prospective study of macular thickness in amblyopic children with unilateral high myopia. Invest Ophthalmol Vis Sci. 2011;52(5):2444-9. doi:10.1167/iovs.10-5555.
14. Cotter SA, Pediatric Eye Disease Investigator Group, Edwards AR, *et al*. Treatment of anisometropic amblyopia in children with refractive correction. Ophthalmology. 2006;113(6):895-903. doi: 10.1016/j.ophtha.2006.01.068.
15. Chen X, Fu Z, Yu J, *et al*. Quantitative analysis of retinal layer optical intensities on three-dimensional optical coherence tomography for central serous chorioretinopathy. Invest Ophthalmol Vis Sci. 2013;54(10):6666-71. doi:10.1167/iovs.13-12073.
16. MOTAS Cooperative. The monitored occlusion treatment of amblyopia study (MOTAS). Br J Ophthalmol. 2002;86(9):952-6. doi:10.1136/bjo.86.9.952.
17. Tugcu B, Araz-Ersan B, Erdogan ET, *et al*. The effect of amblyopia treatment on macular and retinal nerve fiber layer thickness. Int Ophthalmol. 2014;34(4):729-35. doi:10.1007/s10792-013-9868-6.