Case Series

Treatment Outcomes in Serpiginous and Multifocal Serpiginous Choroiditis: Case Series

Naveen Jain, Neelima Mehrotra, Manu Saini, Varun Upadhyay*

Department of Ophthalmology, SRMS-IMS, Bareilly, Uttar Pradesh, India

Abstract

Serpiginous choroiditis (SC) and its tubercular-associated variant, serpiginous-like choroiditis (SLC), represent rare but vision-threatening inflammatory disorders of the choriocapillaris and retinal pigment epithelium. Their recurrent and chronic course, frequent macular involvement, and guarded prognosis make early diagnosis and appropriate therapy crucial.

We present a retrospective case series of five patients with interferon-gamma release assay (IGRA)-positive SLC managed at a tertiary care center between November 2024 and July 2025. All patients were initiated on anti-tubercular therapy (ATT), and systemic corticosteroids were used in tapering doses after physician clearance. In selected cases, posterior subtenon triamcinolone was administered for local control, and one patient received additional azathioprine as a steroid-sparing immunosuppressant.

Treatment compliance emerged as a critical factor influencing outcomes; patients who discontinued or were non-compliant with therapy developed recurrences and further visual decline, while those adhering to therapy demonstrated stabilization of lesions. One patient discontinued azathioprine due to side effects, whereas another showed a favorable response to the drug. Overall, combined ATT and corticosteroid therapy was effective in halting progression, though functional recovery varied depending on the extent of macular involvement. Our findings underscore the need for early recognition, strict adherence to treatment, and long-term follow-up with multimodal imaging to prevent irreversible vision loss. This case series contributes to the growing body of literature on SLC management in tuberculosis-endemic regions, highlighting therapeutic challenges, relapse risk with non-compliance, and the role of adjunctive immunosuppressive agents in refractory cases.

Keywords: Serpiginous choroiditis, Serpiginous-like choroiditis, Ocular tuberculosis, Anti-tubercular therapy, Corticosteroids, Immunosuppressants

Introduction

Tuberculosis (TB), which is caused by *Mycobacterium tuberculosis*, remains a significant public health issue worldwide, especially in endemic areas like South Asia and Africa.[1] Although pulmonary involvement is the most prevalent form, extrapulmonary manifestations, including ocular TB,[2] are also commonly observed. The eye may be affected either through direct hematogenous dissemination of bacilli or through immune-mediated processes.[3] Among the ocular structures, the uveal tract is the most frequently involved due to its abundant vascular supply. TB-related uveitis can manifest as anterior uveitis (characterized by granulomatous keratic precipitates and posterior synechiae), intermediate uveitis (exhibiting vitritis and snowbanking), or posterior uveitis (which may present as choroiditis, retinal vasculitis, or neuroretinitis).[4] Variants of posterior uveitis, such as serpiginous-like choroiditis (SLC), are particularly significant in endemic regions. SLC resembles idiopathic serpiginous choroiditis but is often of tubercular origin.[5] The diagnosis is complex and depends on systemic evaluations (including chest X-ray, sputum analysis, serum calcium, and ACE levels), immunological tests such as IGRA, and multimodal imaging techniques, including OCT, OCT-A, and fundus photography.[6]

Address for correspondence: Varun Upadhyay
Department of Ophthalmology, SRMS-IMS, Bareilly, Uttar Pradesh, India
E-mail: varunupadhyay9@gmail.com

© UPJO, 2026 Open Access This article is licensed under a Creative Commons Attribution 4.0 International License, which permits use, sharing, adaptation, distribution and reproduction in any medium or format, as long as you give appropriate credit to the original author(s) and the source, provide a link to the Creative Commons licence, and indicate if changes were made. The images or other third party material in this article are included in the article's Creative Commons licence, unless indicated otherwise in a credit line to the material. If material is not included in the article's Creative Commons licence and your intended use is not permitted by statutory regulation or exceeds the permitted use, you will need to obtain permission directly from the copyright holder. To view a copy of this licence, visit https://creativecommons.org/licenses/by-nc-sa/4.0/.

How to cite this article: Jain N, Mehrotra N, Saini M, Upadhyay V. Treatment Outcomes in Serpiginous and Multifocal Serpiginous Choroiditis: Case Series. UP Journal of Ophthalmology. 2026;14(3): 172-176.

Received: 06-09-2026, **Accepted:** 22-09-2026, **Published:** 23-10-2026

UP JOURNAL OF OPHTHALMOLOGY
An Official Journal of Uttar Pradesh State Ophthalmological Society, UPSOS (Northern Ophthalmological Society, NOS)

p-ISSN: 2250-1916 | DOI: 10.56692/upjo.2026140309

In the present series, we evaluated 15 suspected patients between November 2024 and July 2025, of which five were confirmed and followed up. They were diagnosed, treated, and monitored with detailed ocular examination, systemic history, chest imaging, laboratory markers, and imaging modalities. Their visual acuity outcomes and systemic associations are presented, emphasizing the importance of early diagnosis, treatment compliance, and combined therapy.[7-9]

Case Presentation

Case 1

A 47-year-old male diagnosed with type 2 diabetes mellitus presented with a gradual loss of vision in both eyes. His best-corrected visual acuity (BCVA) measured 6/18 in both eyes, and the anterior segment exhibited no signs of inflammation. Upon fundus examination, multiple yellowish patches were observed clustered around the optic disc, extending towards the peripheral retina (Figure 1). Laboratory tests indicated a positive IGRA, and a chest X-ray revealed infiltrative changes consistent with pulmonary tuberculosis (Figure 2). The patient commenced anti-tubercular therapy (ATT) and received posterior subtenon (PST) triamcinolone injections (20 mg) at two-week intervals. Initial clinical improvement was observed; however, the patient independently discontinued treatment due to subjective difficulties with color vision. This resulted in a recurrence and further deterioration of visual function. After counseling, he was reinitiated on ATT (excluding ethambutol) along with oral deflazacort. Subsequent follow-up indicated stabilization of disease activity, emphasizing the critical importance of treatment adherence in preventing relapses.

Case 2

A 23-year-old healthy male presented with a one-year history of progressive visual impairment. He reported close contact with a family member diagnosed with pulmonary tuberculosis. At the time of presentation, his BCVA was 6/60 in the right eye and 6/9 in the left. The anterior segment and vitreous were unremarkable.Fundus examination revealed extensive serpiginous lesions with scalloped active borders (Figure 3). IGRA testing returned strongly positive results. A chest X-ray displayed patchy parenchymal opacities in the right mid-zone with ill-defined margins, suggestive of old healed tubercular foci. He had been undergoing ATT for six months but had not adhered consistently, leading to disease progression. ATT was recommenced under supervision, and tapering oral corticosteroids were introduced. Follow-up assessments showed stabilization of disease activity, highlighting the necessity of strict compliance with combined therapy.

Case 3

A 46-year-old female patient with diabetes mellitus reported a four-month history of diminished vision in her right eye. She had previously undergone treatment with high-dose systemic corticosteroids, which did not yield significant improvement, and was still receiving low-dose prednisone (5 mg daily) at the time of referral. Upon examination, best-corrected visual acuity (BCVA) was measured at 6/24 in the right eye and 6/6 in the left eye. Intraocular pressures were within normal limits, and there was an absence of inflammation in the anterior chamber or vitreous. Fundoscopic examination of the right eye revealed multiple yellow-white lesions concentrated in the posterior pole (Figure 4). The interferon-gamma release assay (IGRA) returned positive, and a chest X-ray showed diffuse bilateral reticulonodular opacities (Figure 5). The patient was initiated on standard anti-tuberculosis therapy (ATT) in conjunction with oral prednisone (40 mg/day, approximately 1-mg/ kg). Although minimal regression was noted with prior treatment using triamcinolone, the combination of systemic ATT and corticosteroid therapy resulted in substantial clinical improvement. During follow-up, the lesions showed regression, leaving behind pigmentary scars, and visual acuity remained stable.

Case 4

A 28-year-old man, who had been in good health prior, presented with concerns of dark spots and a painless reduction in vision in both eyes, more pronounced in the left eye, persisting for two months. He mentioned that his father was receiving treatment for pulmonary tuberculosis. Upon examination, best-corrected visual acuity (BCVA) was recorded at 2/60 in the right eye and 1/60 in the left. The anterior segment examination and intraocular pressures were found to be normal. Fundus examination displayed grey yellow subretinal infiltrates that were spreading centrifugally in a serpiginous pattern, characterized by scalloped active borders. The lesions were more pronounced in the left eye, with involvement of the macula. A chest X-ray revealed diffuse bilateral reticulonodular opacities indicative of pulmonary tuberculosis. The patient was administered intravenous methylprednisolone (1 g/day for three days), followed by a tapering regimen of oral prednisolone (60 mg/day). Additionally, he commenced antituberculosis treatment (ATT) under the directly observed treatment, short-course (DOTS) strategy, which included two months of intensive treatment followed by seven months of continuation therapy. After a two-month period, BCVA showed a modest improvement to 3/60 in both eyes, accompanied by a regression of active inflammation. Nevertheless, extensive mottling and atrophy of the retinal pigment epithelium (RPE) were observed, and visual recovery remained limited due to damage to the macula

Case 5

A31-year-old woman experienced a sudden loss of vision in her left eye that persisted for three months. Upon examination, her best-corrected visual acuity (BCVA) was 6/6 in the right eye and 6/60 in the left. Both the anterior segment and intraocular pressures were found to be normal. A fundus examination of the left eye showed a pale, round, yellow-white lesion located at the level of the retinal pigment epithelium (RPE) and outer retina. The optic disc and blood vessels appeared normal.

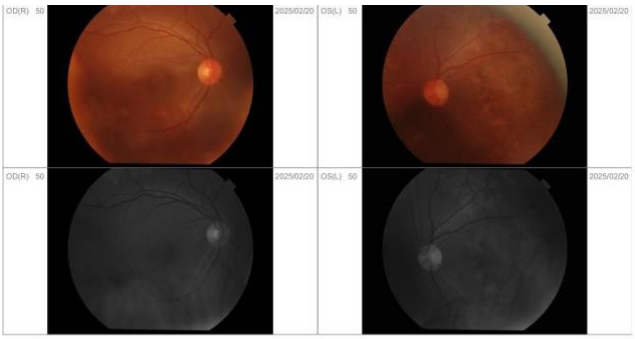

Figure 1: Fundus photograph showing multiple yellowish choroidal lesions clustered around the optic disc with extension toward the periphery, consistent with serpiginous-like choroiditis



Figure 2: Chest X-ray showing infiltrative changes consistent with pulmonary tuberculosis, supporting systemic involvement in a patient with serpiginous-like choroiditis.

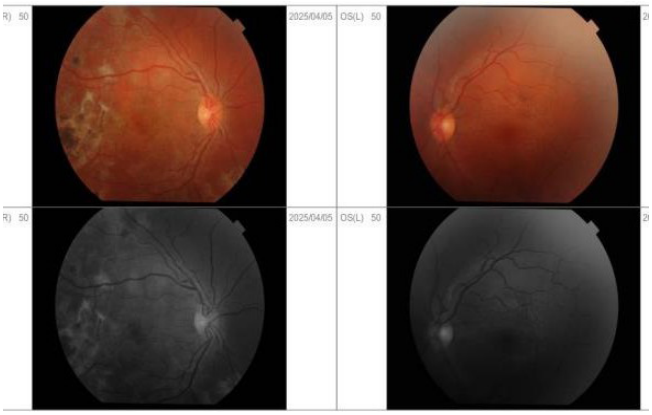

Figure 3: Fundus image demonstrating widespread serpiginous lesions with scalloped active borders, typical of TB-associated serpiginous-like choroiditis.

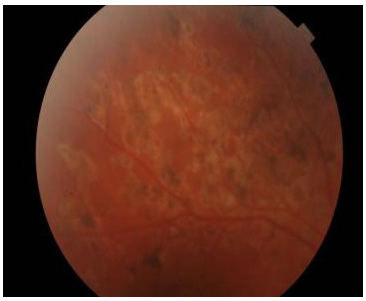

Figure 4: Fundus image displaying grey-yellow subretinal infiltrates with scalloped margins, more extensive in the left eye with macular involvement

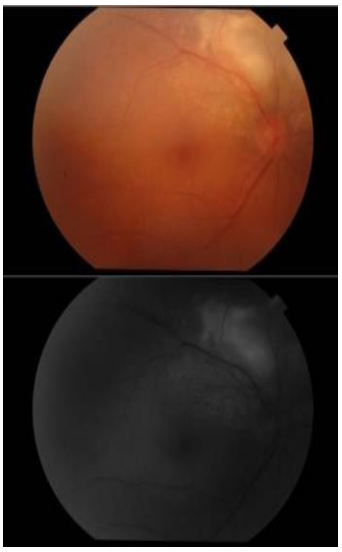

Figure 5: Fundus photograph of the right eye showing multiple yellow-white lesions at the posterior pole

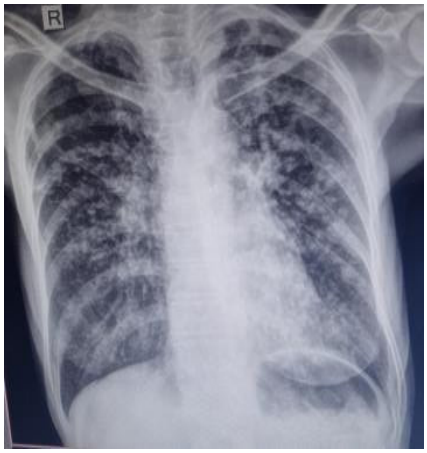

Figure 6: Chest X-ray demonstrating bilateral reticulonodular opacities, indicating pulmonary tuberculosis in a patient presenting with unilateral serpiginous-like choroiditis

Initial laboratory tests, which included VDRL, toxoplasmosis serology, and a chest CT scan, yielded no significant findings. The patient was prescribed oral corticosteroids at a dosage of 1-mg/kg/day, resulting in an improvement of BCVA to 6/24 in the left eye after two months, accompanied by pigmentation of the lesion. She continued on oral prednisone at a dose of

Table 1: Demographic profile, systemic association, fundus findings

Case No.	*Age/Sex*	*Eye involved*	*Systemic association*	*History presenting complaints*	*Fundus findings*
1	47/M	Both eye	Diabetes mellitus	Diminution of vision	Yellowish patches near disc extending to periphery
2	23/M	Both eye	Contact with TB patient, on Non-ATT (6 months compliance)	Progressive vision loss	Widespread choroidal Patches with scalloped borders
3	40/F	Right	Diabetes mellitus	Diminution of vision of vision	Yellow-white lesions in posterior pole
4	28/M	Both eye	Family history of pulmonary TB	Diminution of vision of vision (painless)	Grey yellowish black spots, subretinal infiltrates
5	31/F	Left	None	No TB contact loss of vision (3 months)	Pale, round, yellow-white lesion at RPE/outerretina; disc/vessels

20 mg/day. During follow-up appointments, new cream-colored lesions appeared in the right eye, suggesting a recurrence of the condition. An interferon-gamma release assay (IGRA) was conducted and returned positive, while a chest X-ray indicated no signs of active pulmonary disease. Following a consultation with a pulmonologist, anti-tuberculosis therapy (ATT) was initiated alongside oral corticosteroids at a dosage of 60 mg/day, which was tapered over a period of three months. The lesions showed regression, and no further recurrences were noted in subsequent follow-ups.

Serpiginous-like choroiditis (SLC) is an inflammatory disorder that poses a threat to vision and often indicates a tubercular cause in regions where it is endemic. This condition is marked by recurrent, multifocal choroiditis featuring active advancing edges and scarring, which can ultimately result in cumulative damage to the retinal pigment epithelium (RPE) and irreversible visual impairment if left untreated. Managing SLC is intricate, necessitating a careful distinction between idiopathic autoimmune variants and those linked to Mycobacterium tuberculosis. Our study involving five patients enhances the understanding of treatment outcomes, the importance of adherence to therapy, and the clinical variability associated with this condition.

Discussion

Therapeutic Responses in Our Series

In this case series, all patients were administered anti-tubercular therapy (ATT) alongside corticosteroids, which is fundamental to the management of SLC in areas where tuberculosis is common. Our findings suggest that neither treatment alone is adequate. For example, Case 2 had previously undergone systemic steroid treatment without concurrent ATT, resulting in disease progression, while Case 3 exhibited only slight improvement with local steroid injections until systemic ATT was commenced.

These results align with the observations of Gupta *et al*., who noted that viable tubercle bacilli may remain within the RPE and choroid, underscoring the importance of systemic anti-mycobacterial therapy for the complete eradication of infection.[10,11] Likewise, Basu *et al*. found that patients undergoing combination therapy experienced lower recurrence rates and quicker regression of active lesions compared to those treated solely with corticosteroids[12].

Additionally, Bansal *et al*. emphasized the essential role of ATT in effective disease management[13].

Variability in Functional Outcomes

While appropriate treatment led to a reduction in disease activity, visual outcomes varied significantly. Case 4, which involved bilateral macular involvement, exhibited only minimal improvement despite receiving intravenous steroids and monitored ATT, whereas Case 5, treated prior to macular scarring, showed considerable recovery and maintained stability during follow-up.

Majumder *et al*. referred to SC as an "enigma" due to its unpredictable nature, a sentiment reflected in our series.[7] Even with prompt treatment, the visual prognosis is heavily influenced by the extent of macular involvement at the time of presentation. Vasconcelos-Santos highlighted the critical importance of early initiation of combined therapy to avert irreversible macular damage[5], a reality demonstrated by the contrasting outcomes of Cases 4 and 5.

In our series of five patients, four exhibited an enhancement in visual acuity. Among these individuals, those who received both ATT and steroids while maintaining good compliance achieved the most positive results. This finding reinforces the notion that early detection, swift commencement of combination therapy, and adherence are crucial factors in the effective management of ocular tuberculosis. Prior research has similarly highlighted that timely intervention is associated with improved functional recovery.[12,13]

Role of Compliance and Relapse

Adherence to treatment has emerged as a vital element affecting prognosis. In Case 1, the patient prematurely halted therapy due to subjective visual side effects, resulting in a relapse. In Case 2, inconsistent adherence following the initiation of ATT led to persistent disease activity. Basu *et al.* indicated that relapse was significantly more prevalent among patients who did not complete the entire course of ATT[12], while Bansal *et al*. observed that non-compliance could provoke reactivation of lesions even after initial improvement[13]. Gupta *et al*. further elucidated that incomplete

treatment permits bacilli to remain within the RPE, potentially causing renewed inflammation.[10] Our series corroborates these observations: both instances of non-compliance experienced a resurgence of disease activity, underscoring the necessity of patient education, diligent follow-up, and in certain situations, supervised therapy to guarantee adherence and sustained remission.

Subtenon Steroids as Adjunctive Therapy

Posterior subtenon triamcinolone injections were given to two patients (Cases 1 and 3). Both patients exhibited only partial improvement, with lasting benefits noted only after the introduction of systemic ATT and oral steroids. Sudharshan *et al*. indicated that local steroid administration offers temporary relief but fails to prevent recurrence and cannot substitute for systemictherapy[11]. Likewise, Bansal *et al*. showed that corticosteroid monotherapy frequently led to relapses[13]. These observations imply that subtenon injections may serve as adjunctive therapy in specific cases, particularly when systemic steroids are not an option or as a transitional measure to systemic therapy, but should not be considered the primary treatment approach.

Conclusion

In this series of five patients diagnosed, treated, and followed up for tubercular serpiginous-like choroiditis, our observations highlight the significant challenges in diagnosing and managing this condition in TB-endemic regions. Analysis of previous case reports, series, and original articles reinforces the association between tuberculosis and ocular involvement, emphasizing that systemic infection can manifest in the eye and necessitates prompt recognition.

Successful management in our series required a dual approach of anti-tubercular therapy (ATT) alongside corticosteroids. Monotherapy with either modality often led to relapse or progression, whereas the combination stabilized inflammation and helped preserve visual function. Strict adherence to treatment, early initiation of therapy, and tailored adjunctive measures, such as subtenon steroids when indicated, were critical to achieving favorable outcomes.

Our findings underscore the importance of implementing government-endorsed TB control programs, including DOTS therapy, and highlight the need for regular ophthalmic evaluations in at-risk patients. Relapse was observed in cases with incomplete or inconsistent treatment, demonstrating that non-compliance remains a major risk factor for recurrence.

References

1. World Health Organization, World Health Organization Staff. Global tuberculosis report 2013. World Health Organization; 2013.
2. Shakarchi FI. Ocular tuberculosis: current perspectives. Clinical Ophthalmology. 2015 Nov 26:2223-7.
3. Gupta V, Gupta A, Rao NA. Intraocular tuberculosis—an update. Survey of Ophthalmology. 2007 Nov 1;52(6):561-87.
4. Giovannini A, Mariotti C, Ripa E, Scassellati-Sforzolini B. Indocyanine green angiographic findings in serpiginous choroidopathy. Br J Ophthalmol. 1996 Jun;80(6):536-40
5. Ang M, Vasconcelos-Santos DV, Sharma K, Accorinti M, Sharma A, Gupta A, Rao NA, Chee SP. Diagnosis of Ocular Tuberculosis. Ocul Immunol Inflamm. . 2018; 26(2):208-216.
6. Bansal R, Gupta A, Gupta V, Dogra MR, Sharma A, Bambery P. Tubercular serpiginous-like choroiditis presenting as multifocal serpiginoid choroiditis. Ophthalmology. 2012 Nov 1;119(11):2334-42
7. Majumder PD, Biswas J, Gupta A. Enigma of serpiginous choroiditis. Indian Journal of Ophthalmology. 2019 Mar 1;67(3):325-33.
8. Gupta V, Bansal R, Gupta A. Continuous progression of tubercular serpiginous-like choroiditis after initiating antituberculosis treatment. American Journal of Ophthalmology.2011Nov1;152(5):857-63.
9. Basu S, Elkington P, Rao NA. Pathogenesis of ocular tuberculosis: New observations and future directions. Tuberculosis (Edinb). 2020 Sep;124:101961
10. Gupta V, Gupta A, Rao NA. Intraocular tuberculosis—an update. Survey of Ophthalmology. 2007 Nov 1;52(6):561-87.
11. Sudharshan S, Ganesh SK, Biswas J. Current approach in the diagnosis and management of posterior uveitis. Indian Journal of Ophthalmology. 2010Jan 1;58(1):29-43.
12. Basu S, Nayak S, Padhi TR, Das T. Progressive ocular inflammation following anti-tubercular therapy for presumed ocular tuberculosis in a high-endemic setting. Eye (Lond). 2013 May;27(5):657-62.
13. Bansal R, Gupta A, Gupta V, Dogra MR, Sharma A, Bambery P. Tubercular serpiginous-like choroiditis presenting as multifocal serpiginoid choroiditis. Ophthalmology. 2012 Nov 1;119(11):2334-42.