Photo Gallery

Persistent Fundus Sequelae Seven Months After Central Retinal Artery Occlusion

Ruchi Shukla*, Shantanu Mehrotra, Ashutosh Kumar Mishra

All India Institute of Medical Sciences, Raebareli, Uttar Pradesh, India

Abstract

Central retinal artery occlusion (CRAO) is an ophthalmic emergency characterized by sudden, painless vision loss resulting from acute retinal ischemia and is regarded as the ocular analogue of cerebral stroke. Typical fundus findings include retinal whitening and a cherry-red spot, while chronic sequelae include optic disc pallor, vascular attenuation, and retinal thinning. We present a photo essay of a 45-year-old hypertensive female who presented seven months after sudden unilateral visual loss with persistent retinal changes including a cherry-red spot, perifoveal retinal whitening, localized macular ischemia, retinal hemorrhages, optic disc pallor, and optical coherence tomography (OCT)-documented retinal thinning. This case highlights chronic structural consequences of CRAO and the importance of recognizing delayed post-ischemic sequelae.

Keywords: Central retinal artery occlusion, Cherry-red spot, Retinal ischemia, Optic disc pallor, OCT macula, Retinal thinning

Introduction

Central retinal artery occlusion is an ocular vascular emergency caused by interruption of retinal arterial perfusion, leading to acute retinal ischemia and profound monocular visual loss.[1,2] Classically, acute CRAO manifests with diffuse retinal whitening and a cherry-red spot at the fovea due to retinal opacification surrounding the relatively preserved foveola, where choroidal circulation remains visible.[1,3,5] Long-term sequelae include optic disc pallor, retinal atrophy, vascular attenuation, and irreversible structural changes detectable on OCT.[2,4] Recognition of chronic post-ischemic retinal findings is essential in delayed presentations and may aid diagnosis when the acute phase has passed.

Case Description

A 45-year-old female presented with a history of sudden, painless diminution of vision in the left eye seven months prior to evaluation. She was a known hypertensive with no history of diabetes mellitus, smoking, oral contraceptive use, autoimmune disease, or thromboembolic disorders.

On examination, best corrected visual acuity was 6/12 in the right eye and finger counting close to face (FCCF) in the left eye. Intraocular pressure was 21 mmHg in the right eye and 22 mmHg in the left eye. Anterior segment examination revealed bilateral early immature senile cataract, while the remainder of the examination was unremarkable.

Fundus examination of the left eye demonstrated persistent perifoveal retinal whitening with a prominent cherry-red spot at the macula. A localized ischemic retinal area involving approximately two-disc diameters in the territory supplied by the inferior retinal arcade was noted. Two retinal hemorrhages were visualized along the inferior arcade with associated optic disc pallor suggestive of chronic ischemic damage (Figure 1). Fundus image demonstrating persistent perifoveal retinal whitening with a characteristic cherry-red spot at the fovea (arrow marked 1). A localized ischemic retinal area involving approximately two-disc diameters along the inferior arcade is visible (arrow marked 2), accompanied by retinal hemorrhages (arrow marked 3) and optic disc pallor, representing chronic post-ischemic sequelae of CRAO).

Address for correspondence: Ruchi Shukla
All India Institute of Medical Sciences, Raebareli, Uttar Pradesh, India
E-mail: ruchi.shukla05@gmail.com

© UPJO, 2026 Open Access This article is licensed under a Creative Commons Attribution 4.0 International License, which permits use, sharing, adaptation, distribution and reproduction in any medium or format, as long as you give appropriate credit to the original author(s) and the source, provide a link to the Creative Commons licence, and indicate if changes were made. The images or other third party material in this article are included in the article's Creative Commons licence, unless indicated otherwise in a credit line to the material. If material is not included in the article's Creative Commons licence and your intended use is not permitted by statutory regulation or exceeds the permitted use, you will need to obtain permission directly from the copyright holder. To view a copy of this licence, visit https://creativecommons.org/licenses/by-nc-sa/4.0/.

How to cite this article: Shukla R, Mehrotra S, Mishra AK. Persistent Fundus Sequelae Seven Months After Central Retinal Artery Occlusion. UP Journal of Ophthalmology. 2026;14(3): 177-178.
Received: 10-09-2026, **Accepted:** 26-09-2026, **Published:** 23-10-2026

UP JOURNAL OF OPHTHALMOLOGY
An Official Journal of Uttar Pradesh State Ophthalmological Society, UPSOS (Northern Ophthalmological Society, NOS)
p-ISSN: 2250-1916 | DOI: 10.56692/upjo.2026140310

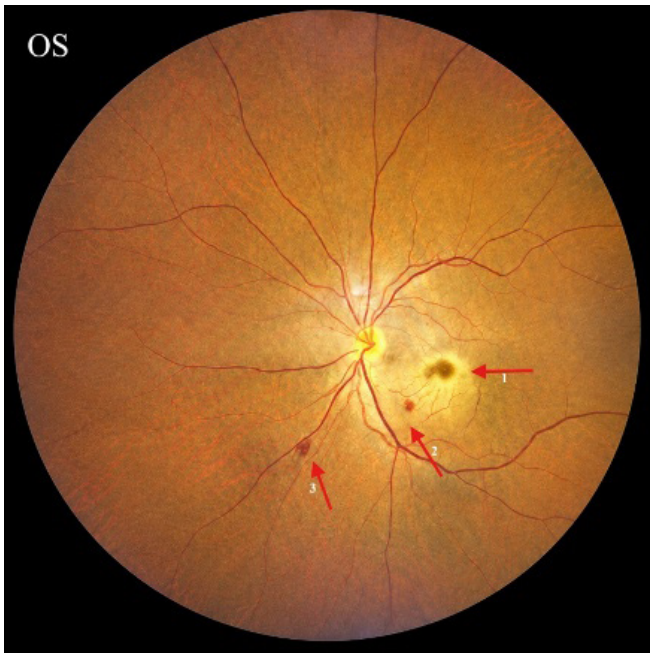

Figure 1: Color fundus photograph of the left eye

Optical coherence tomography of the macula demonstrated retinal thinning consistent with chronic ischemic retinal atrophy (Figure 2).

Macular OCT demonstrating retinal thinning and disruption of normal retinal architecture consistent with chronic retinal ischemia following CRAO.

Chronic thinning of retinal layers following CRAO reflects irreversible neuronal loss after prolonged ischemia.[2,4,6] Laboratory investigations including erythrocyte sedimentation rate (ESR), C-reactive protein (CRP), and lipid profile were within normal limits.

Discussion

CRAO results from interruption of retinal arterial blood flow leading to ischemic injury of the inner retina and sudden, severe visual loss.[1,2] The characteristic cherry-red spot results from retinal edema and opacification surrounding the fovea, which remains relatively transparent due to its thin architecture and preserved choroidal blood supply.[1,5] Although retinal whitening and cherry-red spot are considered hallmark findings of acute CRAO, chronic retinal remodeling may leave persistent structural alterations.[2,4]

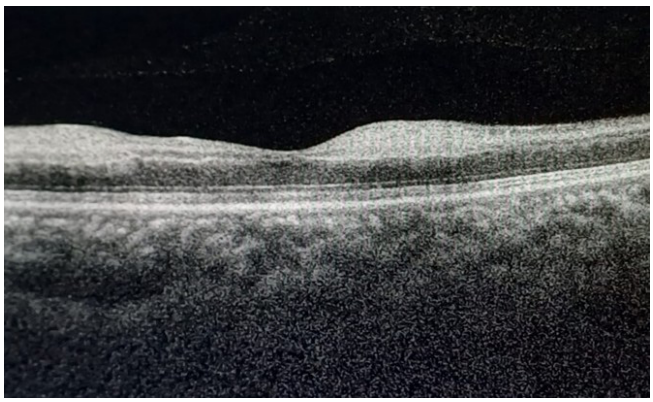

Figure 2: Optical coherence tomography (OCT) macula of the left eye

The present case demonstrates chronic sequelae seven months following the ischemic event, including optic disc pallor and OCT-confirmed retinal thinning, indicating irreversible retinal and optic nerve injury. Persistent retinal thinning on OCT after CRAO has been associated with neuronal degeneration following ischemia.[2,6] Optic disc pallor in delayed presentations reflects chronic neuro-axonal loss secondary to retinal ischemia. [4]

The localized ischemic retinal area in the territory of the inferior arcade may indicate incomplete reperfusion or associated regional retinal vascular compromise. Retinal hemorrhages are uncommon but reported findings in CRAO and may represent vascular instability, reperfusion-related changes, or concomitant retinal ischemic injury.[4,7]

CRAO in relatively younger individuals warrants evaluation for embolic, inflammatory, autoimmune, and hypercoagulable etiologies.[1,2] in this patient, inflammatory markers and lipid profile were within normal limits, with hypertension being the only identifiable systemic vascular risk factor. Hypertension is a recognized vascular risk factor for non-arteritic CRAO.[1,5]

This case highlights the importance of multimodal retinal imaging in documenting delayed structural sequelae of CRAO and reinforces the poor visual prognosis associated with prolonged retinal ischemia.[1,2]

Post-CRAO eyes may demonstrate persistent structural abnormalities long after the acute ischemic event. Recognition of optic disc pallor, retinal thinning, and residual ischemic retinal changes on fundus photography and OCT is important for diagnosis, documentation, and prognostication in delayed presentations.

References

1. Varma DD, Cugati S, Lee AW, Chen CS. A review of central retinal artery occlusion. Eye (Lond). 2013;27(6):688–697.
2. Hayreh SS. Central retinal artery occlusion. Indian J Ophthalmol. 2018;66(12):1684–1694.
3. Tripathy K, et al. Central Retinal Artery Occlusion. StatPearls Publishing; updated 2024.
4. Hayreh SS. Acute retinal arterial occlusive disorders. Prog Retin Eye Res. 2011;30(5):359–394.
5. Cherry-red spot. EyeWiki. American Academy of Ophthalmology. Updated 2025.
6. Shinoda K, Yamada K, Matsumoto CS, Kimoto K, Nakatsuka K. Changes in retinal thickness are correlated with alterations of electroretinogram in eyes with central retinal artery occlusion. Graefes Arch Clin Exp Ophthalmol. 2008;246:949–954.
7. Zvorničanin J, et al. Central retinal artery occlusion and traumatic optic neuropathy. Med Arch. 2018;72(2):146–149.