Case Report

Headache as the Presenting Symptom of Common Carotid Artery Occlusion in a Young Adult

Susaritha Govindan[1], **Fayiqa Ahamed Bahkir**[2]

[1]SRM Medical College Hospital and Research Centre, [2]Eyemed Hospital and Cornea Research Foundation

Abstract

Common carotid artery occlusion (CCAO) is rare in young adults, where the usual etiologies are trauma, arteritis, or hypercoagulable states. We report a 30-year-old male smoker presenting with unilateral headache and ocular pain, later progressing to profound visual loss due to ocular ischemic syndrome (OIS). Carotid Doppler and CT angiography revealed >90% stenosis of the right common carotid artery. This case highlights the importance of considering carotid pathology in young adults with atypical headaches and ocular symptoms.

Keywords : Carotid occlusion, ocular ischemic syndrome, young adult, headache.

Introduction

Carotid artery occlusion is a well-recognized cause of ischemic stroke and ocular ischemic events, most frequently seen in elderly populations with advanced atherosclerosis. [1,2] In young adults, however, common carotid artery occlusion (CCAO) is uncommon and usually related to vasculitis, trauma, dissection, or hypercoagulable states.[3,4]

Ocular ischemic syndrome (OIS) is a rare but vision-threatening manifestation of carotid occlusive disease, resulting from chronic hypoperfusion of the ocular tissues.[5,6] Typical findings include prolonged arm-retina circulation time, mid-peripheral dot hemorrhages, and neo vascularization of the iris.[8] If undetected, it carries a poor visual and systemic prognosis. [16]

Headache, while a nonspecific symptom, may be an early manifestation of carotid occlusion. Fisher reported headache in nearly one-third of patients with internal carotid disease.[7] Awareness of such atypical presentations in younger patients is crucial for timely recognition and referral. We present a case of CCAO in a young adult, initially presenting with unilateral headache and ocular pain.

Case Report

A 30-year-old male smoker presented with right-sided headache and dull ocular/facial pain for one week. There was no history of systemic illness, trauma, or family history of vascular disease. Initial ophthalmological evaluation was normal, and he was treated symptomatically for migraine.

One month later, he developed sudden, severe visual loss in the right eye. Best-corrected visual acuity was hand movements, with a relative afferent pupillary defect. Fundus examination showed an opaque retina with a cherry red spot at the fovea and multiple hypopigmented patches in the periphery (Figure 1).

The left eye was normal. Ocular massage and acetazolamide were attempted but without visual improvement.

Ocular ischemic syndrome was suspected. Fluorescein angiography demonstrated delayed retinal and choroidal filling (Figure 2-4).

Address for correspondence : Fayiqa Ahamed Bahkir
Eyemed Hospital and Cornea Research Foundation
E-mail : fayiqa.prep@gmail.com

© UPJO, 2025 Open Access This article is licensed under a Creative Commons Attribution 4.0 International License, which permits use, sharing, adaptation, distribution and reproduction in any medium or format, as long as you give appropriate credit to the original author(s) and the source, provide a link to the Creative Commons licence, and indicate if changes were made. The images or other third party material in this article are included in the article's Creative Commons licence, unless indicated otherwise in a credit line to the material. If material is not included in the article's Creative Commons licence and your intended use is not permitted by statutory regulation or exceeds the permitted use, you will need to obtain permission directly from the copyright holder. To view a copy of this licence, visit https://creativecommons.org/licenses/by-nc-sa/4.0/.

How to cite this article: Govindan S, Bahkir F, Headache as the Presenting Symptom of Common Carotid Artery Occlusion in a Young Adult UP Journal of Ophthalmology. 2025;13(3): 112-114.

Received: 06-07-25, **Accepted:** 18-10-25, **Published:** 26-10-25

UP JOURNAL OF OPHTHALMOLOGY
An Official Journal of Uttar Pradesh State Ophthalmological Society, UPSOS (Northern Ophthalmological Society, NOS)

p-ISSN: 2250-1916

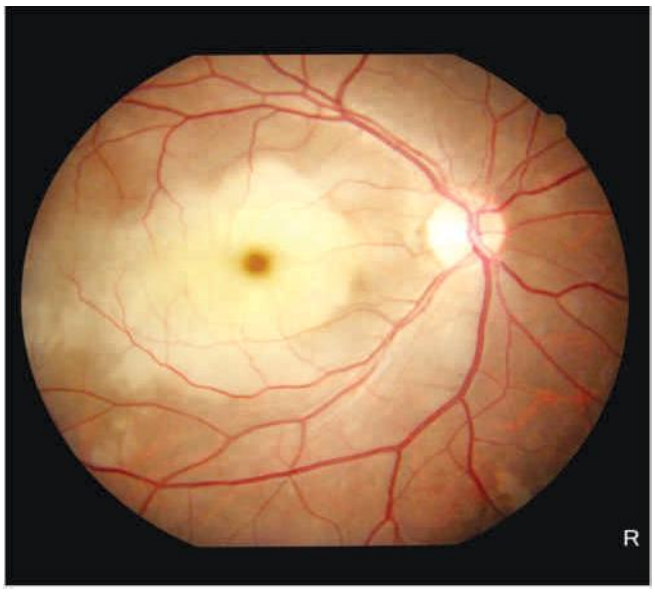

Figure 1 : Fundus photograph of the right eye showing retinal opacification with a cherry-red spot at the fovea and peripheral hypopigmented patches.

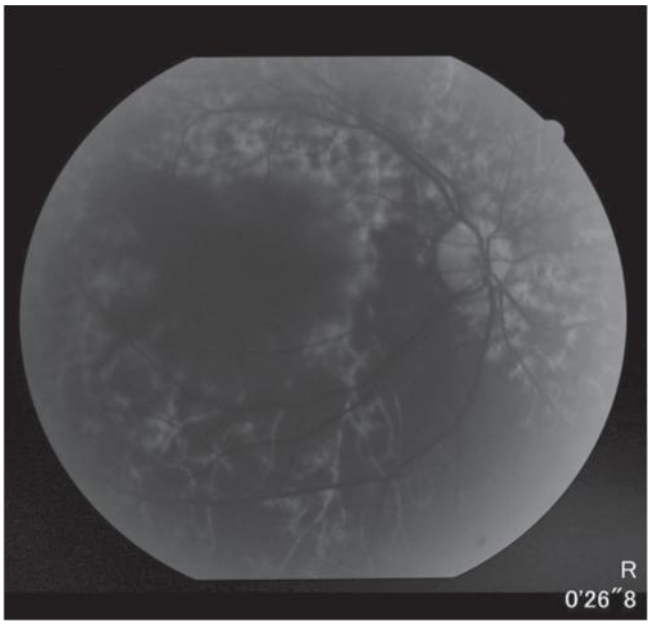

Figure 2 : Fundus photograph of the right eye showing retinalopacification with a cherry-red spot at the fovea and peripheral hypopigmented patches.

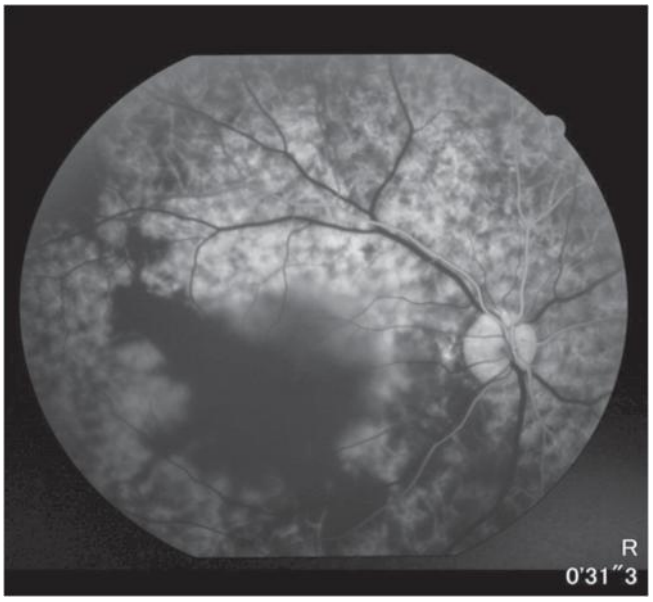

Figure 3 : Mid-phase FFA at 31 seconds, showing sluggish venous filling and patchy perfusion.



Figure 4 : Late-phase FFA at 2 minutes 28 seconds, showing retinal edema and capillary leakage.

Carotid Doppler and CT angiography revealed >90% stenosis of the right common carotid artery. Echocardiography showed only trivial tricuspid regurgitation. The patient was initiated on antiplatelet therapy, anticoagulation, and corticosteroids.

He was referred to a tertiary vascular surgery centre for consideration of carotid endarterectomy.

Discussion

OIS is an uncommon but vision-threatening condition caused by ocular hypoperfusion secondary to severe carotid artery obstruction.[5] Most cases occur in older patients, with >90% stenosis required to produce symptoms.[6] Hayreh and Zimmerman have documented the clinical features of OIS, noting that angiographic signs such as delayed choroidal filling are characteristic.[8] Prognosis is poor: in a systematic review, Terelak-Borys et al. reported a 5-year mortality approaching 40%, largely due to concurrent cardiovascular disease.[16]

In young adults, CCAO is rare, with etiologies including trauma, arteritis, and thrombophilia.[3,4] Kwon et al. demonstrated distinct angiographic features in younger patients, often reflecting non-atherosclerotic mechanisms.[17] In

our case, however, no systemic cause was identified except smoking. While its role remains debated in young patients, large cohort studies such as the ARIC trial have confirmed smoking as a strong accelerator of carotid intimal-medial thickening.[18]

Headache is not traditionally considered a manifestation of carotid disease, but may serve as a sentinel symptom. Fisher reported headache in about one-third of patients with internal carotid occlusion,[7] and Caplan similarly highlighted ocular pain and periorbital discomfort as warning features.[19] The mechanism likely involves altered hemodynamics and collateral recruitment across pain-sensitive vascular territories.[12,13] In our patient, persistent unilateral headache preceded catastrophic vision loss, underscoring the need for vigilance.

Screening for carotid disease in asymptomatic individuals is not recommended by the U.S. Preventive Services Task Force.[11] However, Jonas et al. argued that individualized assessment is warranted in atypical presentations, particularly when ocular or neurological symptoms are unexplained.[20]

While routine screening in the general population may not be justified, clinicians should maintain a low threshold for vascular imaging in such cases.

Conclusion

This case illustrates that unilateral headache and ocular pain in a young adult may herald serious vascular disease. Early consideration of carotid imaging in atypical presentations can prevent irreversible vision loss and potentially reduce cerebrovascular morbidity.

References

1. Klijn CJ, Kappelle LJ, van Huffelen AC, et al. Recurrent ischemia in symptomatic carotid occlusion: prognostic value of hemodynamic factors. Neurology. 2000;55(12):1806-12.
2. Flaherty ML, Flemming KD, McClelland R, et al. Population-based study of symptomatic internal carotid artery occlusion: incidence and long-term follow-up. Stroke. 2004;35(8):e349–52.
3. Nedeltchev K, Baumgartner RW. Carotid artery dissection: pathogenesis, clinical presentation and management. Curr Opin Neurol. 2005;18(1):55-61.
4. Provenzale JM, Sarikaya B. Causes of carotid occlusion in young adults: CT and MR imaging findings. AJNR Am J Neuroradiol. 2009;30(2):334-8.
5. Mizener JB, Podhajsky PA, Hayreh SS. Ocular ischemic syndrome. Ophthalmology. 1997;104(5):859-64.
6. Brown GC, Magargal LE. The ocular ischemic syndrome. Clinical, fluorescein angiographic and carotid angiographic features. Int Ophthalmol. 1988;11(4):239-51.
7. Fisher CM. Headache in occlusion of the internal carotid artery. Neurology. 1958;8(5):435-44.
8. Hayreh SS, Zimmerman MB. Ocular arterial occlusive disorders and carotid artery disease. Ophthalmology Retina. 2017;1(1):12-8.
9. US Preventive Services Task Force. Screening for asymptomatic carotid artery stenosis: recommendation statement. Ann Intern Med. 2014;161(5):356-62.
10. Ruchoux MM, Leys D, Petit H, et al. Pathology of carotid artery occlusion with headache. Stroke. 1990;21(3):397-403.
11. Mas JL, Bousser MG, Hasboun D, Laplane D. Extracranial internal carotid artery occlusion: a study of 68 cases. Stroke. 1986;17(4):713-9.
12. Terelak-Borys B, Skonieczna K, Grabska-Liberek I. Ocular ischemic syndrome – a systematic review. Med Sci Monit. 2012;18(8):RA138-44.
13. Kwon BJ, Han MH, Kang HS, et al. Angiographic features of carotid artery occlusion in young adults. AJNR Am J Neuroradiol. 2005;26(2):308-14.
14. Howard G, Wagenknecht LE, Burke GL, et al. Cigarette smoking and progression of atherosclerosis: the ARIC study. JAMA. 1998;279(2):119-24.
15. Caplan LR. Ocular manifestations of carotid artery disease. Stroke. 1989;20(11):1628-30.
16. Jonas DE, Feltner C, Amick HR, et al. Screening for asymptomatic carotid artery stenosis: updated evidence report and systematic review for the USPSTF. JAMA. 2014;311(18):1901-11.